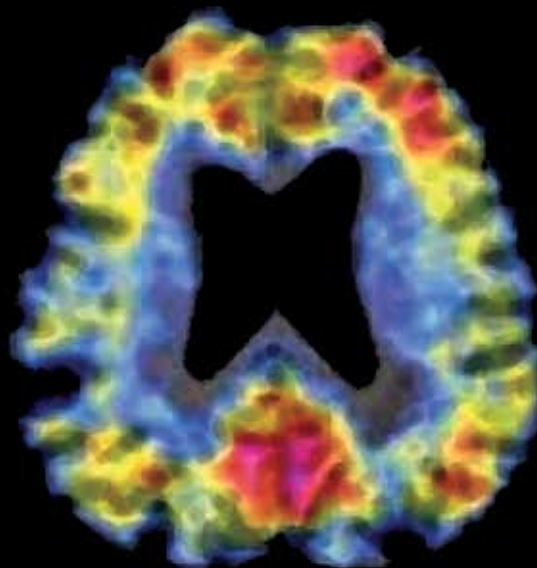
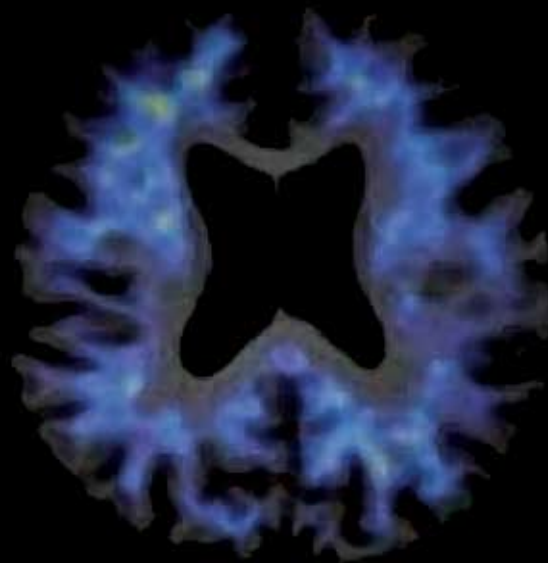
Human Amyloid Imaging • Boston 2007

Friday, May 4th 2007

The Boston Back Bay Hilton Hotel
Belvidere Room

Abstract Book

Schedule - Human Amyloid Imaging, Boston, 2007

07:30 – 08:00 Breakfast

08:00 – 08:15 Introduction Keith Johnson

08:15 – 09:30 Session 1 Keith Johnson, Chair

1. Amyloid Imaging with Pittsburgh Compound-B in Non-demented Elderly Patients
H Aizenstein, University of Pittsburgh
2. Mild Memory Impairments in Normal Subjects with High Cognitive Reserve are Associated with Amyloid Deposition
DM Rentz, Brigham and Women's Hospital, Harvard Medical School
3. Longitudinal Cognitive Change is Associated with Amyloid Deposition Measured by 11-C-PIB
SM Resnick, National Institute on Aging, NIH
4. Imaging of Amyloid Pathology in Prodromal Alzheimer's Disease
A Nordberg, Karolinska Institute, Karolinska University Hospital
5. Parietal Amyloid Deposition Associated with Impaired Memory-Related Functional Activity
RA Sperling, Brigham and Women's Hospital, Harvard Medical School

09:30 – 09:45 General Discussion

09:45 – 10:00 Morning Break

10:00 – 11:15 Session 2 Chester Mathis, Chair

6. PET Amyloid Imaging with [¹¹C]-6-OH-BTA-1 (PIB) in Alzheimer's Disease, Mild Cognitive Impairment, and Healthy Controls
DP Devanand, New York State Psychiatric Institute and College of Physicians and Surgeons, Columbia University
7. Regional Relationships of Amyloid Deposition to Neuropsychological Performance
MA Mintun, Washington University
8. Voxel Based Analysis of PET Amyloid Ligand [¹¹C]PIB Uptake in Alzheimer's Disease
A Bruck, Yale University
9. Evaluation of Data Acquisition Time on the Quantification of [¹¹C]PIB PET
Y Zhou, Johns Hopkins University
10. [¹¹C]-IMPY Imaging to Assess β -Amyloid Burden in Alzheimer's Disease
K Marek, The Institute for Neurodegenerative Disorders, New Haven

11:15 – 11:45 Keynote Presentation by Dennis Selkoe, MD
Vincent and Stella Coates Professor of Neurologic Diseases
Harvard Medical School
Brigham and Woman's Hospital Center for Neurologic Diseases

11:45 – 12:00 General Discussion

12:00 – 13:15 Lunch

13:15 – 14:45 Session 3 William Klunk, Chair

11. Amyloid Deposition Begins in the Striatum of Presenilin-1 Mutation Carriers from Two Unrelated Pedigrees
WE Klunk, University of Pittsburgh
12. Imaging of Amyloid Burden and Distribution in Cerebral Amyloid Angiopathy
KA Johnson, Massachusetts General Hospital, Harvard Medical School
13. Amyloid Deposition in Non-demented, Functionally Stable, Down Syndrome
CA Mathis, University of Pittsburgh
14. Correlation of In Vivo PiB Retention and Postmortem A β Levels: A Case Study
ST DeKosky, University of Pittsburgh
15. In Vivo Detection of Amyloid Deposits in Normals, Mild Cognitive Impairment and Alzheimer's Disease Patients using [^{11}C]BF-227 and PET
H Arai, Tohoku University School of Medicine, Sendai, Japan
16. Imaging Beta Amyloid Deposition In Vivo: Quantitative Comparison of [^{18}F]FDDNP and [^{11}C]PiB
B van Berckel, VU University Medical Centre, Amsterdam, The Netherlands

14:45 – 15:00 Afternoon Break

**15:00 – 15:30 Keynote Presentation by Brad Hyman, MD, PhD
John B Penney Jr Professor of Neurology
Harvard Medical School
Massachusetts General Hospital**

15:30 – 16:45 Session 4 William Jagust, Chair

17. Amyloid Imaging in AD, MCI, DLB, PDD, PD, and FTD using [^{11}C]PiB PET
P Edison, Imperial College London
18. Amyloid Imaging in Distinguishing Atypical Prion Disease from Alzheimer's Disease
AL Boxer, University of California at San Francisco
19. Imaging of Amyloid Plaques and Cerebral Glucose Metabolism in Semantic Dementia and Alzheimer's Disease
A Drzezga, Technische Universität, Munich, Germany
20. [^{11}C]PiB PET in Three Variants of Primary Progressive Aphasia
GD Rabinovici, University of California at San Francisco
21. Amyloid Deposition in the Language System in Early Stage Probable Alzheimer's Disease
R Vandenberghe, KU Leuven, Leuven, Belgium

16:45 – 17:00 General Discussion

Amyloid Imaging With Pittsburgh Compound-B in Non-demented Elderly

H Aizenstein, RD Nebes, JA Saxton, JC Price, CA Mathis, ND Tsopelas, S Ziolko, W Bi, BJ Lopresti, ST DeKosky, E Halligan, WE Klunk

University of Pittsburgh

Background: Clinically silent amyloid accumulation has been found in postmortem biopsies of cognitively healthy elderly adding to the controversy over the primary role for amyloid deposition in Alzheimer's disease (AD). Post-mortem studies do not allow a clear resolution of this controversy, but in vivo PET imaging with recently developed radiotracers that bind selectively to beta-amyloid, such as Pittsburgh Compound-B (PIB), is well-suited to address this problem.

Objective: Initiate longitudinal studies of non-demented elderly to determine the prevalence of amyloid deposition, as assessed by PIB, and relate this to subtle cognitive changes, measured through a battery of detailed neuropsychological tests. This data will serve to help determine whether cognitively normal subjects with amyloid deposition will invariably progress to AD.

Methods: Subjects were evaluated with a neuropsychological battery typical of that used to diagnose AD and MCI. Twenty-six subjects (65-88 y/o) not meeting diagnostic criteria for AD or MCI underwent further detailed cognitive testing to identify more subtle cognitive impairments frequently seen in some elderly. All subjects underwent PIB PET imaging (15mCi, 90min; ECAT HR+). Logan graphical analysis was applied to estimate regional PIB retention (distribution volume, DV), normalized to the cerebellar reference region DV to yield DV ratios (DVRs). MRI was performed for co-registration and partial volume correction.

Results: Of the 26 normal elderly imaged to date, 9 (~35%) showed evidence of early amyloid deposition in at least one brain area using a DVR cut off of 1.5 and verification by the regional pattern on the image. Neurocognitive testing has not yet demonstrated a clear relationship between cognitive performance and amyloid deposition in this small series, but this work is ongoing.

Conclusions: Amyloid deposition can be identified in the cognitively normal elderly during life. We are expanding this series and these amyloid-positive subjects will be followed to determine whether or not they will develop AD in the future.

Mild Memory Impairments in Normal Subjects with High Cognitive Reserve are Associated with Amyloid Deposition

Dorene M Rentz¹, Elisha Eng¹, Erin K Moran², John A Becker², Steven T DeKosky³, William E Klunk³,
Chester A Mathis³, Reisa A Sperling¹, Alan J Fischman², Keith A Johnson^{1,2},

¹Brigham and Women's Hospital, Boston

²Massachusetts General Hospital, Boston

³University of Pittsburgh, Pittsburgh

Contact e-mail: drentz@partners.org

Background: PIB PET imaging reveals amyloid deposition typical of Alzheimer's disease (AD) in some subjects with mild cognitive impairment (MCI) and in some normal controls (NC). We previously reported a series of high-IQ healthy elders in which a subset with very mild memory impairments (MI) was found more likely to decline than those without impairments (MN).

Objective: We hypothesized that MI individuals were more likely than normal subjects without impairments to have levels of amyloid deposition similar to AD and that amyloid burden would correlate with cognitive impairment.

Methods: Fifty older subjects recruited from longitudinal studies of aging and dementia underwent neuropsychological assessment and PIB PET. There were 15 AD, 10 MCI, and 25 highly intelligent (AMNART mean IQ=126) CDR=0 subjects who were classified as having normal memory (NM, n=13) or as being memory impaired (MI, n=12) based on a z score ≥ -1.50 on any Buschke SRT memory subtest normed on highly intelligent individuals. PET was acquired over 60 minutes after injection of 10–15 mCi C11-PIB. PIB retention was expressed as the distribution volume ratio (DVR) with cerebellar gray as reference, and was measured in an aggregate cortical region of interest.

Results: PIB binding was significantly higher in AD than in MCI, MI, or NM groups ($p < 0.001$) and was within the range of AD in 6 of 10 MCI, 9 of 12 MI, and 3 of 13 NM subjects. Interestingly, PIB binding was greater in MI than in MN groups ($p < 0.01$). Among PIB-positive subjects, greater PIB binding was associated with poorer performance on FCSRT memory scores ($r = 0.67$, $p = 0.00$, $r = 0.55$, $p = 0.02$), the Boston Naming Test ($r = 0.57$, $p = 0.02$), Category Generation ($r = .53$, $p = .03$) and Digits Backward ($r = 0.56$, $p = 0.02$) but not Trails A and B or Visual Form Discrimination.

Conclusions: Our findings support the hypothesis that a subset of highly intelligent, normal functioning adults with subtle memory impairment have amyloid deposition. In addition, amyloid burden appears highly correlated with memory, naming, semantic processing and working memory.

Longitudinal Cognitive Change is Associated with Amyloid Deposition Measured by 11-C-PIB

Resnick SM¹, Zhou Y², An Y¹, Ye W², Holt D², Dannals R², Mathis CA³, Klunk WE⁴, Kraut MA², Wong DF².

¹National Institute on Aging, NIH.

²Dept. of Radiology, Johns Hopkins University.

³Dept. of Radiology, University of Pittsburgh.

⁴Dept. of Psychiatry, University of Pittsburgh.

Objective: To investigate whether changes in cognition are associated with amyloid deposition in individuals without dementia.

Method: [¹¹C]PIB images were obtained to measure regional amyloid burden in 33 non-demented participants from the Baltimore Longitudinal Study of Aging (BLSA). Participants were mean (SD) 80.7 (6.4) years of age and included 19 men and 14 women. Six participants (2 men, 4 women) had mild cognitive impairment defined as Clinical Dementia Rating=0.5. To examine [¹¹C]PIB retention in relation to cognitive trajectories over time, a principal component analysis (PCA) was performed on distribution volume ratios across 15 regions, estimated by fitting a simplified reference tissue model to the measured time activity curves. The first principal component score (PIB retention score) contrasted regions of specific (cortex, striatum, thalamus) and non-specific (white matter, midbrain, pons) retention. Mixed effects regression was used to predict cognitive trajectories over time, with the PIB retention score, age at PIB study, and sex as independent predictors.

Results: There was a trend toward an increase in PIB retention score with age ($r=0.32$, $p<0.07$). Greater decline over time in verbal learning and memory, but not visual memory, was associated significantly with higher PIB retention score.

Conclusions: Amyloid deposition is associated with greater longitudinal decline in verbal memory in the prior years. The differential association for verbal but not figural memory may reflect the greater reliance of the California Verbal Learning Test on prefrontal regions, which show early amyloid deposition. The present findings contrast, however, with autopsy results from the BLSA indicating normal cognitive trajectories in individuals who have AD pathology but normal cognition at death. Prospective imaging studies provide the opportunity to identify factors that may distinguish between individuals with neuropathology who go on to develop cognitive impairment versus those who may be exceptionally resistant to disease.

Supported in part by the Intramural Research Program, National Institute on Aging, NIH and by N01-AG-3-2124.

Imaging of Amyloid Pathology in Prodromal Alzheimer's Disease

A.Nordberg,^{1,2} A. Forsberg,¹ H.Engler,³ O.Almkvist,^{1,2} G.Blomquist,³ G.Hagman,² A.Wall,⁴ A.Ringheim,⁴
B. Långström,^{3,4} Karolinska Institutet,¹ Karolinska University Hospital Huddinge,² Stockholm,
Uppsala University,³ Uppsala PET Centre/Uppsala Imanet,⁴ Uppsala, Sweden

From a clinical point of view there is a great need to be able to identify subjects at high risk of developing Alzheimer's disease (AD) as early as possible. Mild cognitive impairment (MCI) is considered to be a transitional phase between normal ageing and dementia disorder. MCI however represent a heterogeneous population of patients with memory impairment where a subgroup are prodromal AD. The amyloid PET ligand ¹¹C-PIB shows a robust difference in PIB retention in cortical brain but also subcortical brain regions of mild AD patients compared to age-matched controls (HC). The cortical retention of ¹¹C-PIB inversely correlates with deficits in cerebral glucose metabolism. When AD patients underwent a 2-year follow-up study with ¹¹C-PIB and ¹⁸F-FDG we observed unchanged PIB retention despite further impairment in cerebral glucose metabolism and in cognition. PIB studies in a group of MCI patients have shown intermediate PIB retention compared to AD and HC. Within the MCI group approximately half of the MCI patient showed high PIB retention similar to AD patients and half PIB retention comparable to HC. Seven out of 11 MCI patients with high PIB retention have after the PET studies at clinical follow up converted to AD. None MCI patients with low PIB retention have converted to AD. A significant correlation was observed between cortical PIB retention and CSF A β ¹⁻⁴² and tau respectively. The MCI patients did not show significant correlation between cortical PIB retention and cerebral glucose metabolism while a significant correlation was observed between PIB retention and episodic memory. By PIB imaging in subject at risk of AD as well as in subject at different stage of AD we will learn more about the time course of evolution of amyloid and its relationship with other pathological event in AD brain including inflammatory processes and neuronal function.

Parietal Amyloid Deposition Associated with Impaired Memory-Related Functional Activity

Reisa Sperling, Pete LaViolette, Eli White, J. Alex Becker, Erin Moran, Julie Price, William Klunk, Chet Matthis, Matt Gregas, Alan Fischman, Dennis Selkoe, Dorene Rentz and Keith Johnson

Amyloid is thought to be a critical factor in the pathophysiological process of Alzheimer's disease (AD), but the relationship of fibrillar amyloid to memory dysfunction in humans remains to be elucidated. We investigated the relationship of amyloid deposition, as assessed by positron emission tomography (PET) with Pittsburgh Imaging Compound B (PIB), to patterns of memory-related neural activity, as assessed by functional magnetic resonance imaging (fMRI). Seventeen older subjects (seven normal controls (NC; CDR 0); five subjects with mild cognitive impairment (MCI; CDR 0.5) and five mild AD patients (AD; CDR 1.0) were imaged with both PIB-PET and fMRI. PIB data was acquired over 60 minutes after injection of 10-15 mCi C11-PIB. Specific PIB binding was calculated using the Logan graphical analysis method yielding a distribution volume ratio (DVR) with cerebellar gray as reference. fMRI data were acquired at 3T during an associative face-name encoding task, and analyzed in SPM2. We found that greater PIB binding was correlated with decreased fMRI activation in the medial temporal lobe (MTL). The relationship between PIB binding in the precuneus and MTL activation was particularly significant in MCI and AD subjects ($R^2 = -0.83$, $t = -6.28$; $p < 0.0002$). Furthermore, classifying subjects dichotomously as PIB+ or PIB-, we also found that PIB+ subjects demonstrated significantly decreased right hippocampal activation, compared to PIB- subjects ($p < 0.003$). We then investigated the relationship of PIB binding to alterations in functional connectivity. Higher levels of PIB binding in the precuneus were associated with greater disruption in the normal pattern of correlated fMRI activity between deactivation in the precuneus and activation of the MTL ($p = 0.007$). These findings in a small number of subjects suggest that amyloid deposition, particularly in the precuneus is associated with failure of memory related activation in the hippocampus and disrupted functional connectivity.

PET Amyloid Imaging with [¹¹C]-6-OH-BTA-1 (PIB) in Alzheimer's Disease, Mild Cognitive Impairment, and Healthy Controls

DP Devanand, M.D.,^{1,2} Ramin Parsey, M.D., Ph.D.,^{1,2} Gregory H Pelton, M.D.,^{1,2} Katrina Cuasay, BA,² JS Dileep Kumar, Ph.D.,^{1,2} Neil Upton, Ph.D.,³ Robert Lai, Ph.D., M.R.C.P., M.F.P.M.,³ Arthur Mikhno, B.S.,^{1,2} Gnanavalli Pradhaban, M.B.B.S.,² Vincenzo Libri, M.D.,³ Roger N Gunn, Ph.D.,³ J John Mann, M.D.^{1,2}

¹New York State Psychiatric Institute

²College of Physicians and Surgeons, Columbia University

³Glaxo Smith Kline, London

e-mail: dpd3@columbia.edu

Objective: To evaluate [¹¹C]-6-OH-BTA-1 (Pittsburgh compound B) PET in patients with Alzheimer's disease, mild cognitive impairment (MCI), and healthy control subjects.

Methods: Outpatients in a memory disorders center who met NINCDS-ADRDA criteria for probable AD (mean MMSE 22 SD 3.2) and published criteria for MCI (mean MMSE 28 SD 1.7) were recruited; age and sex-matched healthy controls (mean MMSE 29 SD 0.9) were recruited by advertisement. A brief neuropsychological test battery was administered and [¹¹C]-6-OH-BTA-1 PET with full quantification was done. MRI was done for coregistration. Distribution volume ratios (DVR) from the Logan graphical method were obtained from PET images coregistered on to their corresponding MRI scans. PET images were modeled using cerebellar gray matter as reference region. Voxel DVR maps were partial volume-corrected using gray, white and CSF probability masks obtained from SPM5 segmented MRI data. Individual DVR estimates were measured for specific anatomical regions drawn on individual MRIs.

Results: Prefrontal cortex DVR in 11 AD patients was greater than in 11 MCI patients ($p < 0.003$) and 12 healthy controls ($p < 0.001$). Prefrontal cortex DVR was comparable in amnesic MCI and AD patients, and comparable in other MCI patients and controls. Age and sex were not associated with prefrontal cortex DVR. Across the entire sample, prefrontal cortex DVR weakly correlated with MMSE total score ($r = -0.25$, $p = 0.19$) but strongly with specific measures of memory: MMSE recall item $r = -0.37$, $p = 0.06$; Selective Reminding Test (SRT) immediate recall $r = -0.47$, $p < 0.02$; SRT delayed recall $r = -0.54$, $p < 0.005$; SRT delayed recognition $r = -0.72$, $p < 0.0001$.

Conclusions: [¹¹C]-6-OH-BTA-1 (PIB) PET scanning can differentiate patients with AD, MCI, and healthy control subjects. The strong correlations between BTA-1 DVR and measures of episodic memory support its potential use in the differential diagnosis of patients with memory disorders.

Distribution of [¹¹C]PIB Uptake in Non-demented subjects

Mark A Mintun, Washington University School of Medicine, Alzheimer Disease Research Center.

Intro: We used PET [¹¹C]PIB imaging to demonstrate that amyloid plaques occur in clinically normal individuals (Mintun et al., 2006) and now show the uptake is in a pattern that is similar but not identical to that seen in demented subjects.

Methods: 80 non-demented subjects (20 to 89 yrs) and 11 subjects diagnosed with dementia of the Alzheimer type (DAT) were evaluated with a 60 min [¹¹C]PIB PET scan. Regions-of-interest were drawn on an MRI over the cerebellar, prefrontal, lateral temporal, occipital, gyrus rectus, precuneus, and striatal cortex. Binding Potential values (BPs) were calculated using Logan graphical analysis with a cerebellar input function. Four regions with the highest BP values in the DAT subjects (prefrontal, temporal, precuneus and gyrus rectus) were averaged to create the Mean Cortical Binding Potential (MCBP).

Results: Non-demented “young” subjects under 59 yrs (n=27) all demonstrated low MCBP values (-0.026 ± 0.062 , max = 0.070). Nondemented subjects above 60 yrs visually appeared to have two distributions of MCBP values. One distribution was uniformly distributed around a BP of zero, and the other distribution was comprised of values greater than 0.16 (which we note is the mean of the young subjects plus three SDs). In this sample, 26% of all subjects over 60 yrs (14 of 53) had abnormal MCBP by this criterion. It was noted that the precuneus had increased relative contribution to the elevated MCBP values in non-demented subjects compared to demented subjects, implying the precuneus may accumulate PIB earlier than other brain regions in the disease process. To examine this hypothesis further, average PIB images of subjects (in standard atlas coordinate system) with elevated PIB uptake (n=14) were compared to those of age-matched subjects with no quantitatively abnormal PIB uptake (n=14). Visually, the comparison demonstrated the precuneus and an area in the ventral prefrontal cortex to have the highest uptake with much less uptake in regions that are typically intense in DAT subjects, such as the gyrus rectus and lateral temporal regions. These data suggest that PIB PET scanning can detect amyloid plaque deposition in the non-demented and that the pattern of deposition is not identical to that seen in the demented subject.

Voxel Based Analysis of PET Amyloid Ligand [¹¹C]PIB Uptake in Alzheimer's Disease

Kemppainen N, MD, PhD¹, Aalto S, MSc^{2,1}, Wilson I, PhD³, Någren K, PhD¹, Helin S, MSc¹, Brück A, MD, PhD¹, Oikonen V, MSc¹, Kailajärvi M, MD, PhD⁴, Scheinin M, MD, PhD⁴, Viitanen M, MD, PhD⁵, Parkkola R, MD, PhD⁶, Rinne JO, MD, PhD¹

¹Turku PET Centre, University of Turku, Turku, Finland,

²Department of Psychology, Åbo Akademi University, Turku, Finland,

³GE Healthcare Medical Diagnostics, United Kingdom,

⁴Department of Pharmacology and Clinical Research Services Turku (CRST), University of Turku, Turku, Finland,

⁵Turku City Hospital, Turku, Finland and Clinical Geriatrics, Karolinska Institutet, Stockholm, Sweden,

⁶Department of Clinical Radiology, Turku University Central Hospital, Turku, Finland

Objective: Our aim was to employ voxel-based analysis method to identify brain regions with statistically significant increases in [¹¹C]PIB uptake in Alzheimer's disease (AD) as compared to healthy control subjects, indicative of increased amyloid accumulation in these regions.

Methods: Seventeen AD patients and 11 control subjects were studied with PET using [¹¹C]PIB as tracer. Group differences in [¹¹C]PIB uptake were analysed with statistical parametric mapping (SPM) and automated region of interest (ROI) analysis.

Results: SPM showed significantly increased uptake ($p < 0.001$) in the frontal, parietal and lateral temporal cortices, as well as in the posterior cingulate and striatum. No significant differences in uptake were found in the primary sensory and motor cortices, primary visual cortex, thalamus and the medial temporal lobe. These results were supported by automated ROI analysis, with most prominent increases in AD subjects in the frontal cortex and posterior cingulate followed by the parietal and temporal cortices and striatum, as well as small increases in the occipital cortex and thalamus.

Interpretation: Voxel-based analysis revealed widespread distribution of increased [¹¹C]PIB uptake in AD. The findings of this study are in accordance with the distribution and phases of amyloid pathology in AD, previously documented in post mortem studies.

Evaluation of Data Acquisition Time on the Quantification of [¹¹C]PIB PET

Yun Zhou¹, Weiguo Ye¹, James Basic¹, Mohab Alexander¹, Susan M Resnick², Dean F Wong¹

¹Dept. of Radiology, Johns Hopkins University.

²National Institute on Aging, NIH.

Objective: To evaluate effects of data acquisition time on quantification of [¹¹C]PIB PET to minimize the PET scanning period.

Methods: Ninety-minute [¹¹C]PIB dynamic PET was performed in 28 controls and 6 individuals with mild cognitive impairment (MCI). Regions of interest (ROI) for cerebellum (reference tissue) and 15 other ROIs were defined on coregistered MRI's and applied to dynamic images. [¹¹C]PIB retention in brain tissue was measured as the tracer distribution volume ratio (DVR). Three reference tissue methods were used to estimate DVR:

- 1) a simplified reference tissue model (R_1, k'_{2R}, BP) with spatial constraint on k'_{2R} (the efflux rate constant in cerebellum) (SRTMpc); The Marquardt algorithm was used to fit SRTMpc to all 15 ROIs TACs simultaneously. The estimates from SRTMpc were obtained by fitting SRTMpc to the measured tracer kinetics in [0 30], [0 45], [0 60], [0 75], [0 90]; DVR was calculated as $BP+1$ after model fitting.
- 2) The Logan plot, [40 60], [40 75], [40 90], linear portion was used to estimate DVR; and
- 3) Concentration ratio (CR) of target to reference tissue on times of [0 20], [20 40], [40 60], and [60 90]. These methods were applied to ROI and pixel kinetics.

Results: Based on the ROI TAC analysis, the highest linear correlation among the DVR estimates from SRTMpc([0 T]), Logan plot of [40 T], and CR([40 T]) were obtained at $T \geq 60$ min. DVR images generated by CR method showed that DVR[0 20] were significantly different from [40 60] in both control and MCI groups. Based on SRTMpc ROI analysis, the statistical power to distinguish between controls and MCI tends to be stable when the PET data acquisition is at least 60 minutes.

Conclusion: DVR estimates from 60 min [¹¹C]PIB PET scans were as reliable as those from 90 min scans.

Supported in part by the Intramural Research Program, National Institute on Aging, NIH and N01-AG-3-2124 and K24 DA00412.

[I-123] IMPY Imaging to Assess β -Amyloid Burden in Alzheimer's Disease

Kenneth Marek, Danna Jennings, Andrei Koren, Gilles Tamagnan, Daniel Skovronsky, John Seibyl
The Institute for Neurodegenerative Disorders, Molecular NeuroImaging New Haven
CT, AVID Pharmaceuticals, University of Pennsylvania, Philadelphia, Pennsylvania

Objective: To evaluate [I-123] IMPY (6-iodo-2-(4'-dimethylamino-)phenyl-imidazo[1,2-]pyridine) as an objective and quantifiable biomarker of β -amyloid deposition in Alzheimer's disease (AD) subjects and healthy controls (HC).

Background: β -Amyloid plaque accumulation likely plays a critical role in AD etiology, and potentially in AD therapy. Imaging tracers targeting β -amyloid would provide improved diagnostic accuracy and enable monitoring of amyloid reducing therapies for AD. IMPY is a modified thioflavin derivative with good binding affinity to preformed synthetic A*1-40 aggregates, excellent brain uptake, and selective plaque labeling in AD transgenic mouse models and in postmortem AD brain sections.

Methods: In this ongoing study AD patients and HC undergo serial SPECT imaging after either a single bolus injection or a bolus injection followed by multiple mini-bolus injections of [I-123] IMPY. Subjects were evaluated prior to imaging with MMSE, ADAS-Cog. After the single bolus injection, 13 serial, dynamic SPECT acquisitions were acquired over 2 hours. During the bolus plus mini-bolus injections, scans were acquired for 90 minutes. All images within each reconstructed data set were aligned with SPM. Results were based on a standardized cortical volume of interest protocol. Venous blood was obtained to assess free plasma IMPY and metabolites.

Results: 15 subjects; 8 AD patients (mean age 80, gender -6F,2M, mean MMSE 23) and 7 HC (mean age 69, gender -2F,,5M, mean MMSE 29) have undergone [I-123] IMPY imaging. Following bolus injection cortical time activity data shows rapid uptake and washout. Analysis shows a T1/2 washout of [I-123] IMPY of 21.5 minutes (sd 5.3) for HS and 39.3 minutes (sd 19) for AD ($p=.052$). Preliminary analysis of equilibrium distribution volume showed mean cortical to cerebellar ratios of 1.25 in AD subjects compared to 1.06 in HS.

Conclusion: This pilot [I-123] IMPY study demonstrates a 25%–100% signal difference between well-characterized AD patients and older HC depending on the imaging outcome. These data suggest the feasibility of distinguishing AD and HC using quantitative [I-123] IMPY imaging outcomes. However, additional studies are required to more fully validate [I-123] IMPY as a potential tool for AD onset and progression.

Supported by grants from the Alzheimer's Association and Pfizer Pharmaceuticals

Disclosures

K Marek and J Seibyl have an equity interest in Molecular NeuroImaging
D. Skovronsky is an employee of AVID Pharmaceutical

Amyloid Deposition Begins in the Striatum of Presenilin-1 Mutation Carriers from Two Unrelated Pedigrees

WE Klunk, JC Price, CA Mathis, ND Tsopelas, BJ Lopresti, SK Ziolk, W Bi, JA Hoge, MD Ikonovic, JA Saxton, BE Snitz, DA Pollen, M Moonis, CF Lippa, JM Swearer, KA Johnson, DM Rentz, AJ Fischman, HJ Aizenstein, ST DeKosky.

University of Pittsburgh and University of Massachusetts and Massachusetts General Hospital (Radiology)

Background: Post-mortem pathological studies have provided a retrospective reconstruction of the natural history of amyloid deposition in Alzheimer's disease (AD). While these studies have been very valuable, recently developed PET imaging radiotracers such as Pittsburgh Compound-B (PIB) now allow prospective natural history studies of amyloid deposition in living subjects. Although it is difficult to predict which cognitively normal elderly may be destined for brain amyloid deposition, carriers of mutations in the presenilin-1 (PS1) gene are known with certainty to be destined for AD and the accompanying amyloid pathology.

Objective: To determine the early stages of the natural history of amyloid deposition in carriers of PS-1 mutations that cause autosomal dominant early-onset familial AD (eFAD).

Methods: Three asymptomatic and five symptomatic carriers of PS1 eFAD mutations (C410Y or A426P) and two unaffected siblings were clinically evaluated at the University of Pittsburgh Alzheimer Disease Research Center and two more asymptomatic carriers (C410Y) were evaluated at MGH. PIB PET imaging (15mCi, 60 min) was then performed (ECAT HR+ or GE PC4096-WB). Standardized uptake value ratios normalized to the pons ($SUVR_{pons}$) were calculated to estimate regional PIB retention. MRI was performed for co-registration.

Conclusions: Intense, focal PIB retention was found in the striatum of all ten presenilin-1 mutation carriers and this retention averaged $246 \pm 32\%$ of the control mean (range: 184-294%; $p=2.4 \times 10^{-7}$). About half of the presenilin-1 mutation carriers, three of them asymptomatic, had higher striatal PIB retention than all sporadic Alzheimer's disease subjects thus far studied. In most presenilin-1 mutation carriers, PIB retention also was elevated in neocortical brain areas compared to controls, but not to the degree observed in sporadic Alzheimer's disease subjects. The two presenilin-1 mutation carriers with a clinical diagnosis of early-onset Alzheimer's disease did not yet show the typical regional pattern of PIB retention observed in mild, sporadic Alzheimer's disease. Post-mortem evaluation of tissue from two affected parents of PS1-C410Y subjects in this study confirmed extensive striatal amyloid deposition, in addition to typical cortical deposition.

Imaging of Amyloid Burden and Distribution in Cerebral Amyloid Angiopathy

Johnson KA, MD,^{1,2,3,4} Gregas M, PhD,⁵ Becker JA, PhD,¹
Kinnecom K, MS,² Salat DH, PhD,^{1,4} Moran EK, BA,¹ Smith EE, MD,^{2,4} Rosand J, MD, MSc,^{2,4} Rentz DM, PsyD,^{3,4}
Klunk WE, MD, PhD,⁶ Mathis CA, PhD,⁷ Price JC
PhD,⁷ DeKosky ST, MD,⁸ Fischman AJ, MD, PhD,^{1,4} Greenberg SM MD, PhD^{2,4}

¹Departments of Radiology and ²Neurology, Massachusetts General Hospital,

³Department of Neurology, Brigham and Women's Hospital, Boston

⁴Harvard Medical School, Boston

⁵Harvard School of Public Health, Boston,

Departments of ⁶Psychiatry, ⁷Radiology, and ⁸Neurology,
University of Pittsburgh Medical Center, Pittsburgh

Objectives: Cerebrovascular deposition of β -amyloid (cerebral amyloid angiopathy, CAA) is a major cause of hemorrhagic stroke and a likely contributor to vascular cognitive impairment. We evaluated PET imaging with the β -amyloid-binding compound Pittsburgh Compound B (PIB) as a potential non-invasive method for detection of CAA. We hypothesized that amyloid deposition would be observed with PIB in CAA and, based on the occipital predilection of CAA pathology and associated hemorrhages, that specific PIB retention would be disproportionately higher in occipital lobes.

Methods: We compared specific cortical PIB retention in 6 non-demented subjects diagnosed with probable CAA to 15 normal controls and 9 patients with probable Alzheimer's disease (AD). Results: All CAA and AD subjects were PIB-positive, both by distribution volume ratio (DVR) measurements and by visual inspection of PET images. Global cortical PIB retention was significantly elevated in CAA (DVR 1.18 ± 0.06) relative to NC (1.04 ± 0.10 ; $p=0.0009$), but was lower in CAA than in AD (1.41 ± 0.17 , $p=0.002$). The ratio of occipital to global PIB, however, was significantly greater in CAA than AD (99 ± 0.07 vs 0.86 ± 0.05 , $p=0.003$).

Interpretation: We conclude that PIB-PET can detect cerebrovascular β -amyloid and may serve as a method for identifying the extent of CAA in living subjects.

Amyloid Deposition in Non-demented, Functionally Stable Down Syndrome

Chester A. Mathis, Benjamin L. Handen, Umapathy Channamalappa, Nicholas D. Tsopelas, Sheila Cannon, Peter Bulova, Scott K. Ziolk, Wenzhu Bi, Julie C. Price, Steven T. DeKosky, William E. Klunk

University of Pittsburgh

Background: Individuals with Down syndrome (DS) are at high risk for developing AD due to the presence of an extra copy of chromosome 21, which codes for the A β precursor protein (APP) gene. Postmortem studies have documented the presence of AD pathology in 60-90% of adults with DS (with greater pathology increasing with age). Additionally, symptoms of AD occur in over 40% of DS individuals between 50 and 59 years of age. Thus, the study of adults with DS provides a valuable opportunity to follow the natural history of amyloid deposition and compare it to clinical symptomatology—knowing that about half of the group will eventually develop clinical AD and an even greater fraction will develop amyloid deposits.

Objective: To determine whether amyloid imaging with Pittsburgh Compound-B PIB can detect amyloid deposition in the brains of non-demented, functionally stable DS subjects.

Methods: Six non-demented, functionally stable DS subjects (ages 20, 22, 34, 35, 38 and 44) were clinically evaluated at the University of Pittsburgh Down Syndrome Center to verify the absence of dementia. PIB PET imaging (15mCi) was then performed (ECAT HR+). Data was acquired from 40-60 min post-injection. Standardized uptake value ratios normalized to the cerebellum (SUVR) were calculated to estimate regional PIB retention. MRI was performed for co-registration.

Conclusions: An AD-like pattern of amyloid deposition was observed in the 44 y/o DS subject. A striatal-predominant pattern of amyloid deposition, similar to that observed in carriers of presenilin-1 mutations that cause early-onset AD was observed in the 38 y/o subject. No amyloid deposition was detected in the four youngest subjects. These findings confirm that amyloid deposition can be detected in non-demented, functionally stable DS subjects and that the prevalence of detectable amyloid may be low until above age 30.

Correlation of In Vivo PIB Retention and Postmortem A β Levels: A Case Study

ST DeKosky, CA Mathis, JC Price, MD Ikonovic, RL Hamilton, EE Abrahamson, WR Paljug, ML Debnath, CE Hope, BA Isanski, ND Tsopelas, BJ Lopresti, S Ziolk, W Bi and WE Klunk

University of Pittsburgh Departments of Neurology, Psychiatry, Radiology and Pathology

Background: The retention of Pittsburgh Compound-B (PIB) is higher in AD patients than cognitively normal controls in brain areas known from previous pathology studies to be high in A β plaques (e.g., frontal, precuneus, parietal and temporal cortices). Likewise, PIB retention is the same in AD and controls in brain areas known to have very little A β deposition (e.g., cerebellum and white matter). Despite this apparent relationship, direct correlation of *in vivo* PIB retention and post-mortem A β levels in the same subject remains to be shown. Here we report a post-mortem study of the first Pittsburgh subject who was studied with PIB PET imaging and later came to autopsy.

Objective: To examine regional correlations of *in vivo* [C-11]PIB retention measures with post-mortem quantifications of [H-3]PIB binding and A β levels in tissue homogenates, and immunohistochemical analysis of amyloid load.

Methods: A 63 y/o female patient with severe AD (MMSE=1 at the time of PIB scan) died 10 months later (age 64) from causes unrelated to the PIB study (60 min scan). Autopsy consent had been pre-arranged and frozen tissue was banked from the right hemisphere and the entire left hemisphere was formalin-fixed. The frozen tissue was homogenized and divided for total A β ELISA and [H-3]PIB binding. The formalin-fixed tissue was analyzed with A β immunohistochemistry.

Results: In all 14 brain regions examined, there was a strong direct correlation of *in vivo* PIB retention (expressed as Logan distribution volume ratio with cerebellum as reference; DVR) with *in vitro* measurements of A β levels ($r=0.8$; $p<0.001$) and [H-3]PIB binding ($r=0.8$; $p<0.001$). A β levels and [H-3]PIB binding correlated very well with each other ($r=0.9$; $p<0.00001$). Semi-quantitative immunohistochemical analysis supported these findings, showing increased β -amyloid load in brain areas with high PIB DVR values and low amyloid load in areas with low DVR values.

Conclusions: PIB retention *in vivo* correlates well with the amount and distribution of A β in brain tissue. This finding strongly supports the current *in vivo* data suggesting that PIB PET is a reliable indicator of brain A β deposition.

In Vivo Detection of Amyloid Deposits in Normals, Mild Cognitive Impairment and Alzheimer's Disease Patients Using [¹¹C]BF-227 and PET

Hiroyuki Arai, Nobuyuki Okamura, Manabu Tashiro, Kazuhiko Yanai, Yukitsuka Kudo;
Tohoku University School of Medicine, Sendai , Japan

Background and aims: Progressive accumulation of amyloid- β peptide is earliest and most fundamental event for Alzheimer's disease (AD) pathogenesis. Thus, *in vivo* detection of amyloid deposits using positron emission tomography (PET) would prove to be useful for prevention of AD, tracking disease progression and monitoring treatment effect of anti-amyloid therapy. The purpose of this study is to evaluate the diagnostic utility of a novel PET imaging probe, 2-[2-(2-dimethylaminothiazol-5-yl)ethenyl]-6-[2-(fluoro)ethoxy]benzoxazole (BF-227), in patients with AD as well as old normal subjects and mild cognitive impairment (MCI).

Methods: Binding affinity of BF-227 to amyloid- β (A β) fibrils was calculated. Binding property of BF-227 to amyloid plaques was examined by staining of AD brain sections. For clinical utility of [¹¹C]BF-227, 10 normal subjects, 10 subjects with MCI and 10 patients with AD participated in this study which had been approved by local IRB. Dynamic PET images were obtained for 60 min following injection of [¹¹C]BF-227. Regional standardized uptake value (SUV) and the ratio of regional to cerebellar SUV were calculated as an index of [¹¹C]BF-227 retention. Regional tracer distribution of AD patients and MCI subjects was compared with normal subjects on a voxel-by-voxel basis by statistical parametric mapping.

Results: BF-227 displays high binding affinity to aggregated A β fibrils ($K_d = 0.73$ nM). BF-227 binds to relatively matured plaques with or without cores and it also weakly binds to so-called diffuse plaques. Binding to neurofibrillary tangles was nearly negligible. The clinical PET study demonstrated retention of this tracer in cerebral cortices of AD patients, but not in those of normal subjects. All AD patients were clearly distinguishable from normal individuals using temporal cortical SUV ratio. Cortical BF-227 retention in MCI subjects was heterogeneous and exhibited either AD-like or control-like patterns. A patient with frontotemporal dementia (FTD) showed no cortical retention of BF-227, whereas a patient with Creutzfeldt-Jakob disease was positive with a different pattern from AD. A voxel-by-voxel analysis of PET images demonstrated that cortical BF-227 retention in AD patients is found in posterior brain regions that were known to be preferential sites of amyloid deposits.

Conclusions: Our findings suggest that [¹¹C]BF-227 may be a promising PET probe for *in vivo* imaging of amyloid deposits.

Imaging Beta Amyloid Deposition In Vivo: Quantitative Comparison of [¹⁸F]FDDNP and [¹¹C]PIB

Nelleke Tolboom,^{1,2} Maqsood Yaqub,¹ Wiesje van der Flier,² Ronald Boellaard,¹ Gert Luurtsema,¹ Albert D. Windhorst,¹ Frederik Barkhof,³ Philip Scheltens,² Adriaan A. Lammertsma,¹ Bart N.M. van Berckel¹

¹Departments of Nuclear Medicine & PET Research,

²Neurology & Alzheimer Centre, and Radiology³,

VU University Medical Centre, Amsterdam, The Netherlands

Introduction: Both [¹⁸F]FDDNP and [¹¹C]PIB have been developed as PET tracers for imaging and quantifying beta-amyloid (A β) fibril accumulation in Alzheimer's disease (AD) in vivo.^{1,2} The purpose of the present study was to compare the potential value of [¹⁸F]FDDNP and [¹¹C]PIB in the (early) diagnosis of AD by performing paired studies in the same patients.

Methods: In this ongoing study, dynamic 90 minutes 3D [¹¹C]PIB and [¹⁸F]FDDNP scans were acquired on the same day using an HR+ (Siemens) PET scanner. During both scans, continuous on-line and discrete manual sampling was performed to derive a metabolite corrected arterial plasma input curve. For each subject, volumes of interest (VOI) were defined on an individually acquired, co-registered T1 weighted structural MRI scan using an automated procedure.³ Preliminary analysis of time-activity curves was performed using the simplified reference tissue model with cerebellum grey matter as reference tissue. Binding potential (BP) was used as outcome measure, in particular for areas previously associated with AD: frontal, parietal and temporal cortex.

Results: At present, three AD patients, three patients with mild cognitive impairment (MCI) and three age matched normal controls were included. Results are summarised in figures 1 and 2. [¹¹C]PIB showed good contrast between AD patients and normal controls, as described previously.¹ In addition, the range of BP values in MCI patients was broader, probably due to the known heterogeneity of this group.⁴ [¹⁸F]FDDNP provided less contrast between AD patients and normal controls. In AD patients, [¹¹C]PIB BP was in general tenfold higher than [¹⁸F]FDDNP BP.

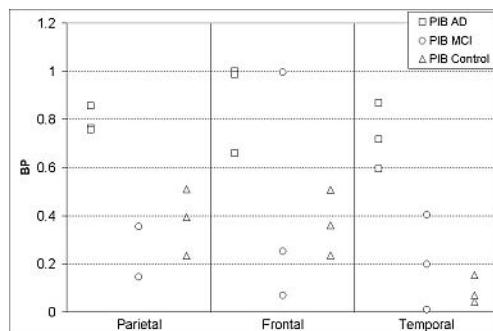


Figure 1

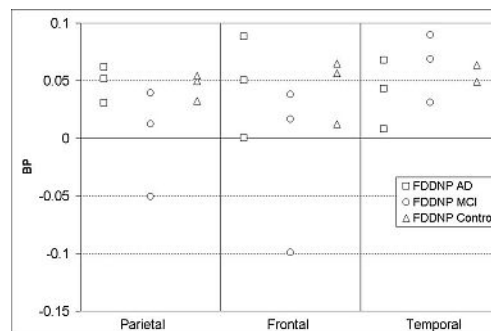


Figure 2

Conclusion: The difference in BP between AD patients and normal controls appears to be more pronounced for [¹¹C]PIB than for [¹⁸F]FDDNP. Further studies are needed to substantiate these preliminary findings.

References

1. Shoghi Jadid *et al* (2002) *Am J Geriatr Psychiatry* 10: 24-35.
2. Klunk *et al* (2004) *Ann Neurol* 55: 306-319.
3. Svarer *et al* (2005) *NeuroImage* 24: 969-979.
4. Price *et al* (2005) *J Cereb Blood Flow Metab* 25: 1528-47.

Amyloid Imaging in AD, MCI, DLB, PDD, PD, and FTD using ¹¹C-PIB PET

Paul Edison¹, Juha Rinne², Christopher C Rowe³, Hilary Archer⁴, Victor L Villemagne², Aren Okello¹, Imtiaz Ahmed¹, Nick Fox⁴, Angus Kennedy¹, Martin Rossor⁴, David J Brooks¹.

¹MRC Clinical Sciences Centre and Division of Neuroscience, Imperial College London

²Turku PET centre, University of Turku, Finland

³Centre for PET, Austin Health, Melbourne and Colin L Masters - Dept. Pathology, University of Melbourne

⁴Dementia Research centre, University College London

Background: ¹¹C-PIB is a thioflavin PET tracer which binds to fibrillar beta-amyloid with nanomolar affinity. The presence of amyloid plaques and neurofibrillary tangles is the pathological hallmark of Alzheimer disease. Amyloid pathology is, however, also associated with other dementias in varying proportions.

Aim: To assess the prevalence of increased amyloid load in Alzheimer disease (AD), amnesic mild cognitive impairment (MCI), dementia with Lewy bodies (DLB), Parkinson's disease with later dementia (PDD), non-demented Parkinson's disease and frontotemporal dementia (FTD).

Methods: 36 AD, 22 MCI, 13 DLB, 12 PDD, 10PD, 6FTD and 42 control subjects (50-82yrs) were recruited. Each subject underwent detailed clinical evaluation, neuropsychological assessment, T1 and T2 MRI and a 90 minute ¹¹C-PIB PET scan. Amyloid load was quantitated as 60-90' target:cerebellar uptake ratios (RATIO). Object maps were created by segmenting individual MRIs and spatially transforming the grey matter images into standard stereotaxic MNI space and then superimposing a probabilistic atlas. Cortical ¹¹C-PIB uptake was assessed by ROI (region of interest) analysis.

Results: Individually 33 out of 36 AD subjects showed significant 50-100% increases in cingulate, frontal, temporal, parietal and occipital cortical ¹¹C-PIB uptake. 13 out of 22 MCI subjects showed significant (50-100%) AD levels of increase in cortical ¹¹C-PIB uptake while 9 had normal scans. 10 out of 13 DLB patients and 2 out of 12 PDD patients showed an increased amyloid load in cortical regions. None of the non-demented PD subjects or FTD subjects showed any significant increase in brain ¹¹C-PIB uptake. Three of the 42 age-matched control subjects showed borderline increases in ¹¹C-PIB uptake in cingulate cortex.

Conclusion: ¹¹C-PIB differentiates 90% of clinically probable AD cases from healthy controls while 60% of amnesic MCI subjects also show a significantly raised amyloid load approaching AD levels. However a significantly raised amyloid load was also seen in 75% of DLB subjects which is consistent with reported neuropathological studies. This suggests that ¹¹C-PIB PET imaging is not a specific diagnostic tool for AD but rather will allow us to target those dementia subjects who might benefit from emerging anti-amyloid agents.

Amyloid Imaging in Distinguishing Atypical Prion Disease from Alzheimer's Disease

Adam L Boxer, MD, PhD¹, Gil D Rabinovici, MD¹, Vladimir Kepe, PhD²,
Jill Goldman, MS, MPhil, CGC³, Ansgar J Furst, PhD⁴, S.-C. Huang, DSc², Suzanne L.
Baker, PhD⁵, James P O'Neil, PhD⁵, Helena Chui, MD⁶, Michael D Geschwind, MD, PhD¹, Gary W Small, MD⁷,
Jorge R Barrio, PhD², William Jagust, MD^{1,4,5} and Bruce L Miller, MD¹

¹Memory and Aging Center, Department of Neurology, University of California, San Francisco

²Department of Molecular and Medical Pharmacology, David Geffen School of Medicine, University of California, Los Angeles

³Gertrude H. Sergievsky Center at Columbia University, College of Physicians and Surgeons, New York

⁴Helen Wills Neuroscience Institute, University of California, Berkeley

⁵Lawrence Berkeley Laboratory

⁶Department of Neurology, University of Southern California

⁷Center on Aging, Semel Institute for Neuroscience and Human Behavior, David Geffen School of Medicine, University of California, Los Angeles

Objective: To compare the *in vivo* uptake of two amyloid-binding PET agents, PIB and FDDNP, in human subjects with a prion protein (PrP) gene (PRNP) mutation that produces a clinical syndrome similar to Alzheimer's Disease (AD).

Background: Amyloid imaging with specific PET ligands offers great promise for early detection and differential diagnosis of AD. Genetic forms of prion disease can present with clinical features that resemble AD, and at autopsy may show deposition of mutant PrP-amyloid. FDDNP binds to PrP amyloid in post-mortem human specimens, but has not been reported *in vivo* in prion disease. The ability of PIB to bind PrP-amyloid is not known.

Methods: Two brothers with a 6-octapeptide repeat insertion mutation (6-OPRI) in the PRNP gene underwent clinical, structural MRI and FDG-PET evaluations. One brother received a PIB-PET evaluation, while the other received an FDDNP-PET scan. PET results were compared with 5 normal and 5 AD individuals scanned with either agent.

Results: PIB uptake was similar to controls in one brother, while FDDNP uptake was intermediate between AD and controls in the other brother.

Conclusions: Different amyloid-binding agents may have differential sensitivity to prion-related brain pathology. A combination of amyloid imaging agents may be useful in the diagnosis of early-onset dementia.

Imaging of Amyloid-Plaques and Cerebral Glucose Metabolism in Semantic Dementia and Alzheimer's Disease

Alexander Drzezga MD¹; Timo Grimmer MD²; Gjermund Henriksen PhD¹,
Isabelle Stangier MS¹, Robert Perneczky MD², Janine Diehl-Schmid MD²,
Chester A Mathis PhD³, William E Klunk MD PhD⁴, Hans-Jürgen Wester PhD¹,
Markus Schwaiger MD¹ and Alexander Kurz MD²

¹Department of Nuclear Medicine; Technische Universität, Munich,

²Department of Psychiatry and Psychotherapy; Technische Universität, Munich,

³Department of Radiology; University of Pittsburgh, Pittsburgh,

⁴Department of Psychiatry, Western Psychiatric Institute & Clinic, Pittsburgh, 1000

Background: Semantic dementia (SD) is a rare clinical subtype of the frontotemporal lobar degenerations (FTLD). Some overlap of clinical symptoms and imaging findings between SD and Alzheimer's dementia (AD) has been shown and a reliable differentiation of the underlying pathology can not be guaranteed based on clinical examination. However, histopathological analysis has not revealed the deposition of amyloid-Plaques in most SD-cases. Our aim was to determine differences between AD and SD by means of *in vivo* imaging of amyloid-Plaque deposition and cerebral glucose metabolism.

Methods: Patients with AD (n=8) and with SD (n=8), matched for gender, age and overall degree of cognitive impairment, were recruited using established clinical criteria. Cerebral glucose metabolism was examined with [F-18]FDG-PET, cerebral amyloid-Plaque load was assessed using [C-11]6-OH-BTA-1 (PIB)-PET. A volume of interest analysis (VOI), using the cerebellum as a reference region, and voxel-based statistical group comparisons (SPM2) were carried out between the patient groups (FDG- and PIB-PET data) and a group of healthy controls (FDG-PET data).

Results: Characteristic patterns of hypometabolism could be demonstrated in both groups (AD: bilateral temporoparietal and frontal cortex; SD: left>right temporal, frontal mesial cortex) with some regional overlap, particularly in temporal cortices. In contrast, strong [C-11]PIB tracer binding was observed only in AD (bilateral temporoparietal and frontal cortex, posterior cingulate, precuneus) but not in SD. This stronger amyloid-Plaque deposition in AD, clearly extended the metabolic differences between the groups, even in regions with comparable metabolic deficits.

Conclusions: These findings support the notion that neuronal dysfunction is associated with amyloid-Plaque deposition in AD but not in SD. Amyloid-Plaque imaging may be valuable to characterize dementias *in vivo*, based on the underlying pathology rather than on neuropsychological findings. This may be important for definition prognosis and for the selection of patients for scientific trials.

[¹¹C]PIB PET in Three Variants of Primary Progressive Aphasia

GD Rabinovici, MD^{1,2}; ML Gorno-Tempini, MD PhD^{1,2}; AJ Furst, PhD^{3,4}; NF Dronkers, PhD^{5,6}; JM Ogar, MS⁵; EC Mormino, BS³; RA Lal, BS³; Paras Patel, BS³; BL Miller, MD^{1,2} and WJ Jagust, MD^{3,4}

From the Memory and Aging Center¹ and Department of Neurology², University of California at San Francisco; Helen Wills Neuroscience Institute³, University of California at Berkeley; Lawrence Berkeley National Laboratory⁴; Center for Aphasia and Related Disorders, VA Northern California Health Care System, Martinez, CA⁵; Department of Neurology and Linguistics, University of California at Davis⁶.

Background: The logopenic variant of primary progressive aphasia (PPA) is associated with temporoparietal atrophy and the ApoE4 genotype, suggesting it may be caused by Alzheimer's disease (AD). We used [¹¹C]PIB PET to test whether A β amyloid is more prevalent in logopenic aphasia (LPA) than in the other PPA variants, progressive non-fluent aphasia (PNFA) and semantic dementia (SD).

Methods: Patients meeting PPA criteria (Mesulam) were classified as LPA (N=3, ages 57-63), PNFA (N=3, ages 55-80) or SD (N=4, ages 58-81). All patients underwent [¹¹C]PIB and [¹⁸F]FDG PET. PIB distribution volume ratios (DVRs) were calculated using Logan graphical analysis (cerebellar reference region). FDG images were normalized to pons. Partial volume correction was applied to PET data using patient MRIs.

Results: 3/3 LPA, 1/4 SD and 0/3 PNFA patients demonstrated elevated PIB on visual inspection blinded to diagnosis (whole brain DVRs 1.36-1.51 for positive scans, 0.99-1.06 for negative scans). "PIB-positive" patients showed tracer uptake throughout frontal, parietal and lateral temporal cortex, similar to the pattern reported in "typical" AD. Tracer uptake was symmetric (mean DVRs: frontal— left 1.70 ± 0.13 , right 1.69 ± 0.16 ; parietal— left 1.67 ± 0.10 , right 1.63 ± 0.08 ; temporal—left 1.63 ± 0.08 , right 1.56 ± 0.12). LPA patients showed decreased FDG uptake in left greater than right temporoparietal cortex, SD patients demonstrated left greater than right anterior temporal hypometabolism, while PNFA patients had either normal FDG uptake (n=1) or lesions in left frontal operculum (n=2).

Conclusions: The logopenic variant of PPA is associated with elevated cortical PIB, suggesting this variant may be caused by AD pathology. When present, PIB uptake in PPA is symmetric and similar to "typical" AD, while FDG patterns are often asymmetric and vary by sub-type. These preliminary findings need to be confirmed in a larger cohort and in autopsy-confirmed cases.

Amyloid deposition in the language system in early-stage probable Alzheimer's disease

Natalie Nelissen^a, Mathieu Vandebulcke^a, Patrick Dupont^b, Ron Peeters^c, Koen Van Laere^b, Guy Bormans^d, Rik Vandenberghe^a

^aLaboratory for Cognitive Neurology,

^bNuclear Medicine Department,

^cRadiology Department,

^dLaboratory for Radiopharmacy K U Leuven, Leuven, Belgium

Post-mortem measures of amyloid deposition correlate only weakly with cognitive dysfunction ante-mortem in patients with Alzheimer's disease (AD). We tested the hypothesis that functional reorganisation, measured with fMRI, forms a critical intermediary step between amyloid-associated brain injury and clinical disease expression.

Fifteen patients with early-stage probable AD (MMSE 24.6±2.7) and 16 matched controls participated in this combined fMRI and PET study. The fMRI experiment had 2 factors: task (associative-semantic versus visuo-perceptual judgment) and stimulus modality (words versus pictures)¹. Contrast images were created by comparing associative-semantic conditions to the visuo-perceptual baseline.

Neuritic amyloid deposition was measured by Pittsburgh Compound B (PIB)-PET scans acquired dynamically over 90 minutes. PIB-uptake was voxel-wise quantified using Logan graphical analysis (cerebellar cortex as reference region).

Patients were compared to controls by two-sample t-tests (SPM2). Simple linear regressions (SPM2) were used to determine correlations between fMRI response or PIB uptake and picture naming accuracy (Boston Naming Test (BNT) score) in AD. In addition to a whole brain search, the posterior third of the left superior temporal sulcus (STS), an area showing hypoactivity during associative-semantic processing in patients with mild cognitive impairment¹, was used as a-priori volume of interest.

In the left STS, the fMRI response during associative-semantic processing was lower in AD than in controls (-66,-39,-6, $P_{SVC}=0.031$), and correlated inversely with PIB-uptake ($r=-0.56$, $P=0.029$). Contralaterally, in the right posterior STS, the fMRI response was higher in AD than in controls (63,-18,0, $P_{SVC}=0.019$). The degree to which patients were able to recruit this area correlated positively with picture naming performance (54,-24,0, $r=0.84$, cluster $P_{corrected}=0.014$). PIB-uptake in temporal cortex or elsewhere didn't correlate with BNT scores ($P_{uncorrected}>0.01$).

In conclusion, the degree of neuroplasticity and functional reorganisation in temporal cortex determines clinical word finding difficulties in AD more than amyloid deposition *per se*.

¹Vandebulcke *et al*, Cereb Cortex 2006